



57^è 
Société de Geriatrie
de l'Ouest et du Centre

Journées
de FORMATION et de RECHERCHE
de **GÉRONTOLOGIE**
de l'Ouest et du Centre

Maladie d'Alzheimer?
Mon œil!

Florian MARONNAT
CHRU Brest

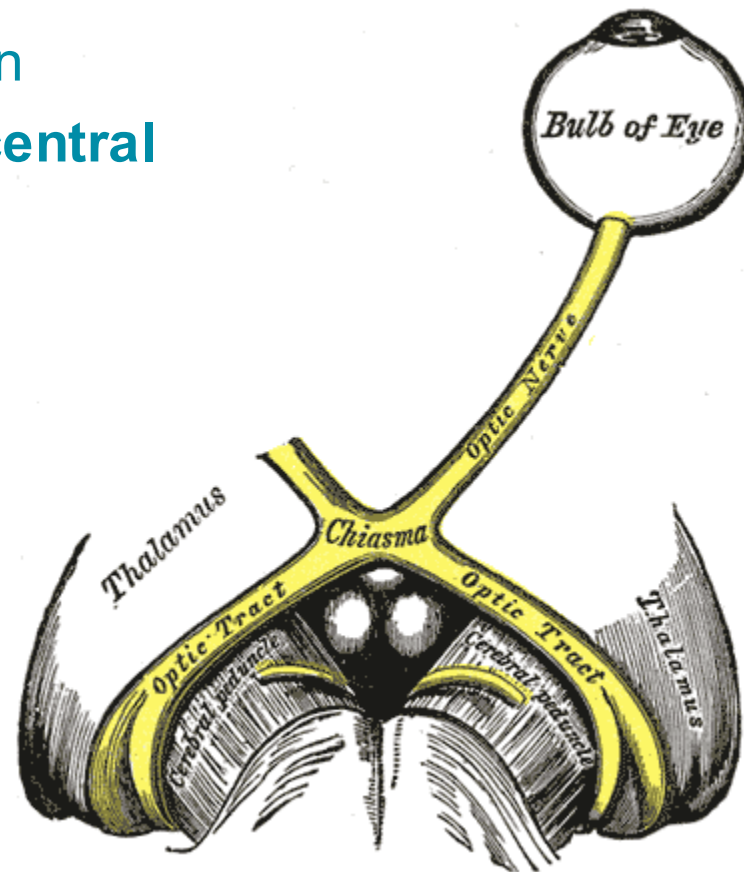
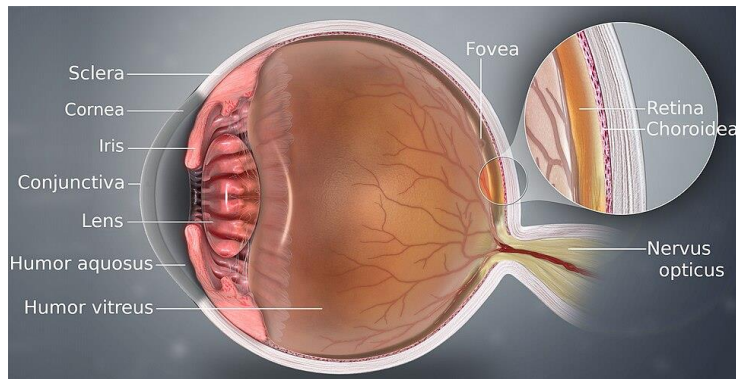


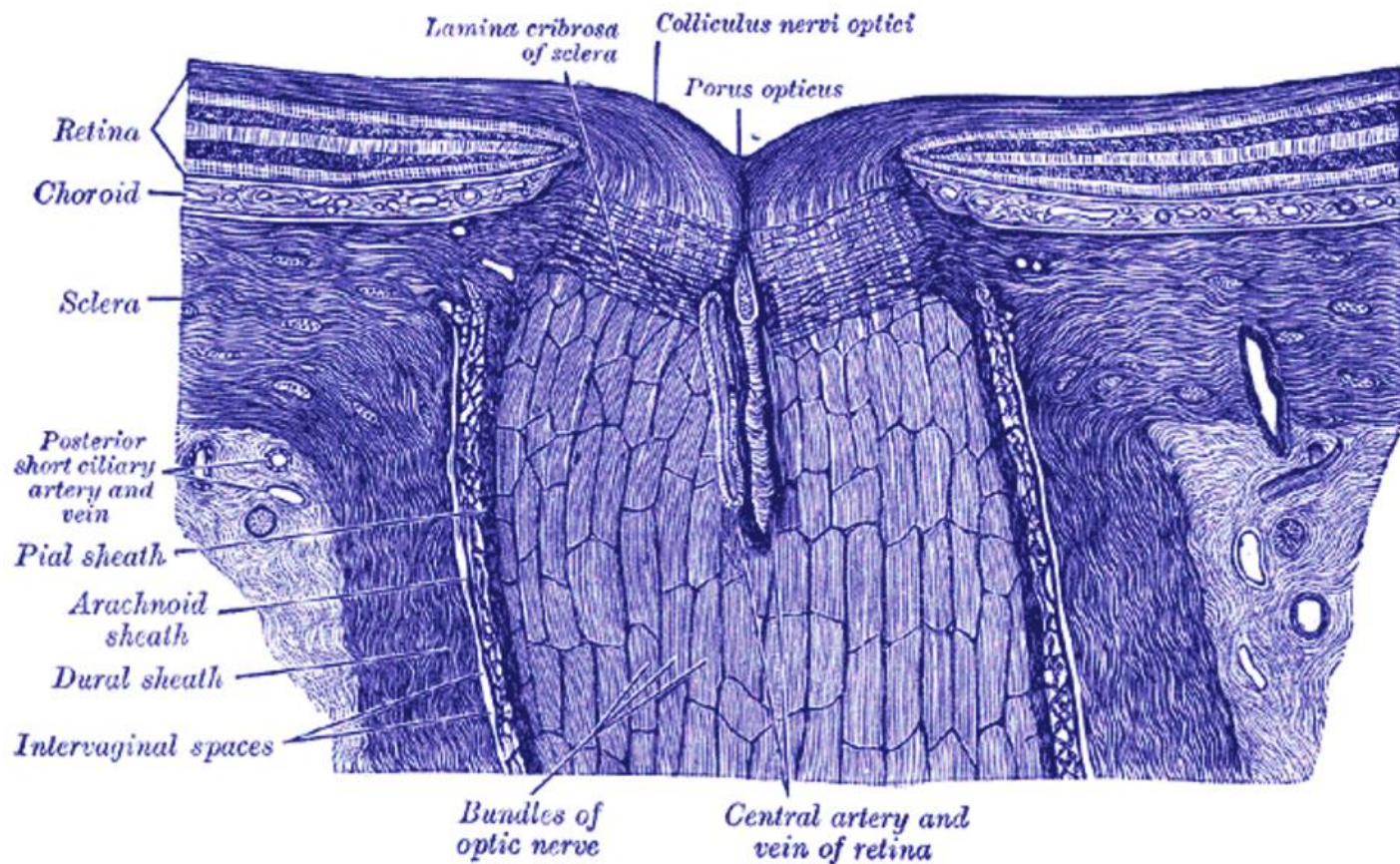
Conflits d'intérêts

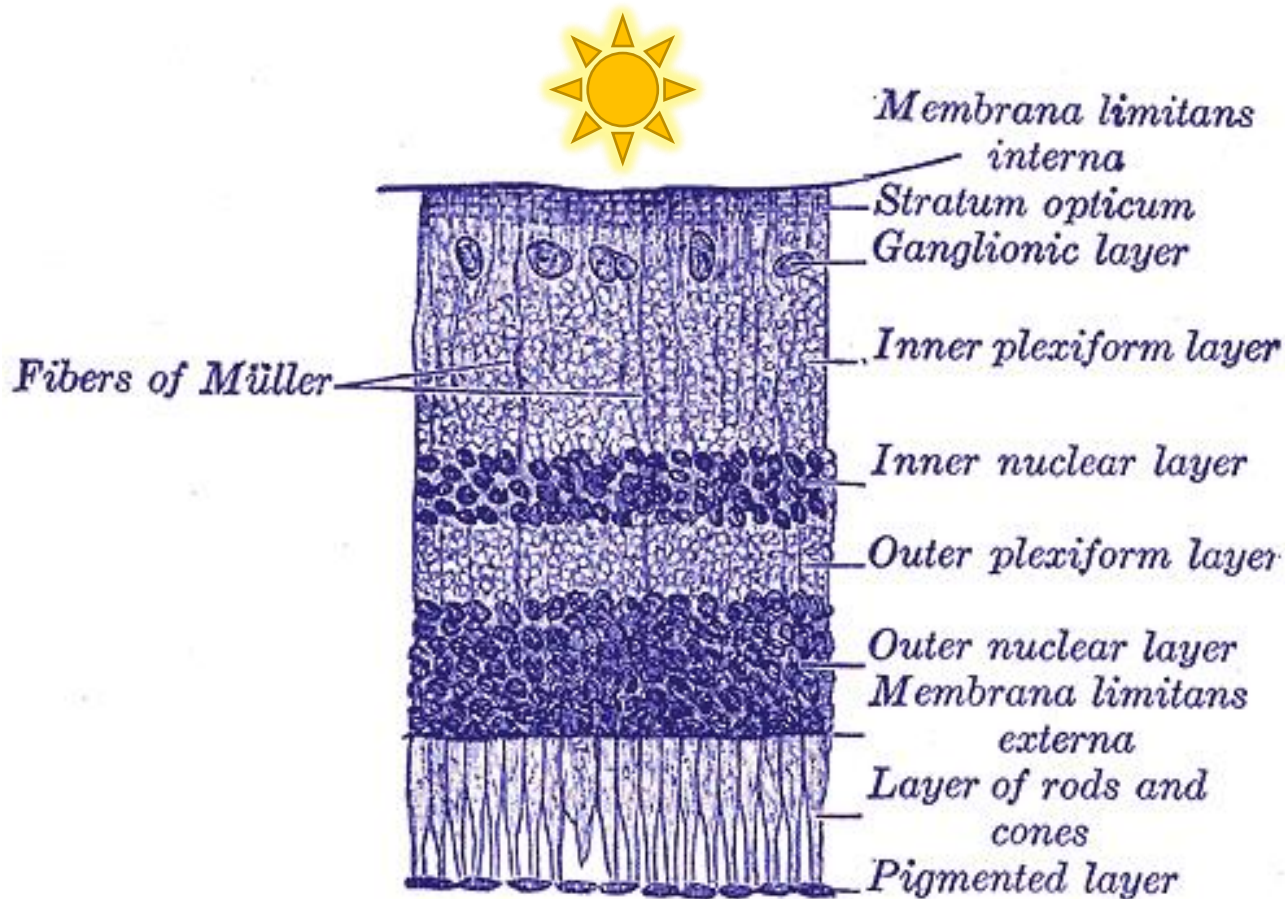
- Aucun



- Nerf optique = nerf II = nerf crânien
- Appartient au **système nerveux central**



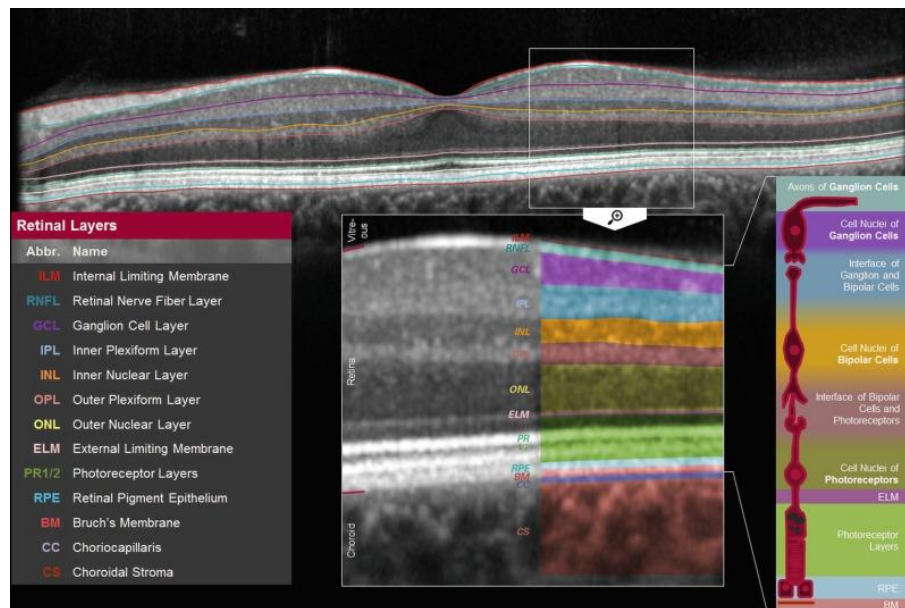






Rappels sur l'OCT (Optical Coherence Tomography)

- Onde électromagnétique, Proche de l'infrarouge
- Résolution élevée (μm)
- Rapide
- Indolore



(Aumann S et coll, New Frontiers in Biomedical Optics, 2019)



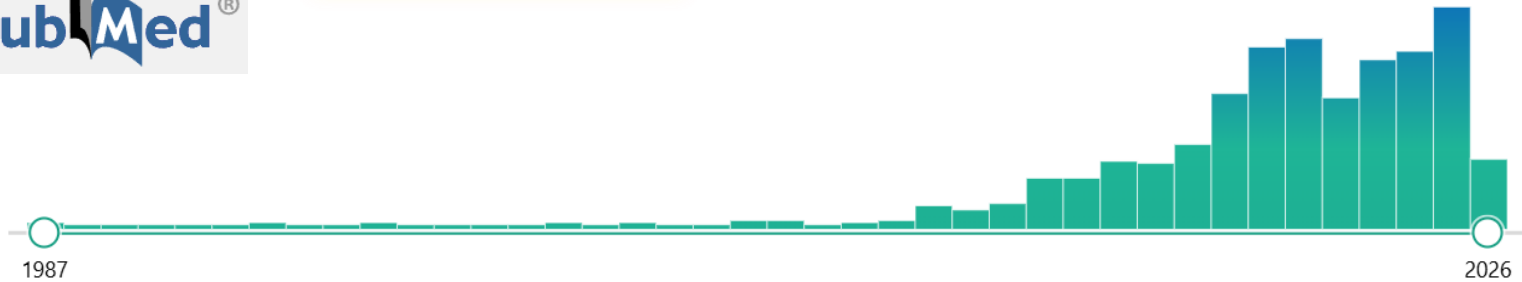
Lien entre nerf optique – OCT – Maladie d'Alzheimer

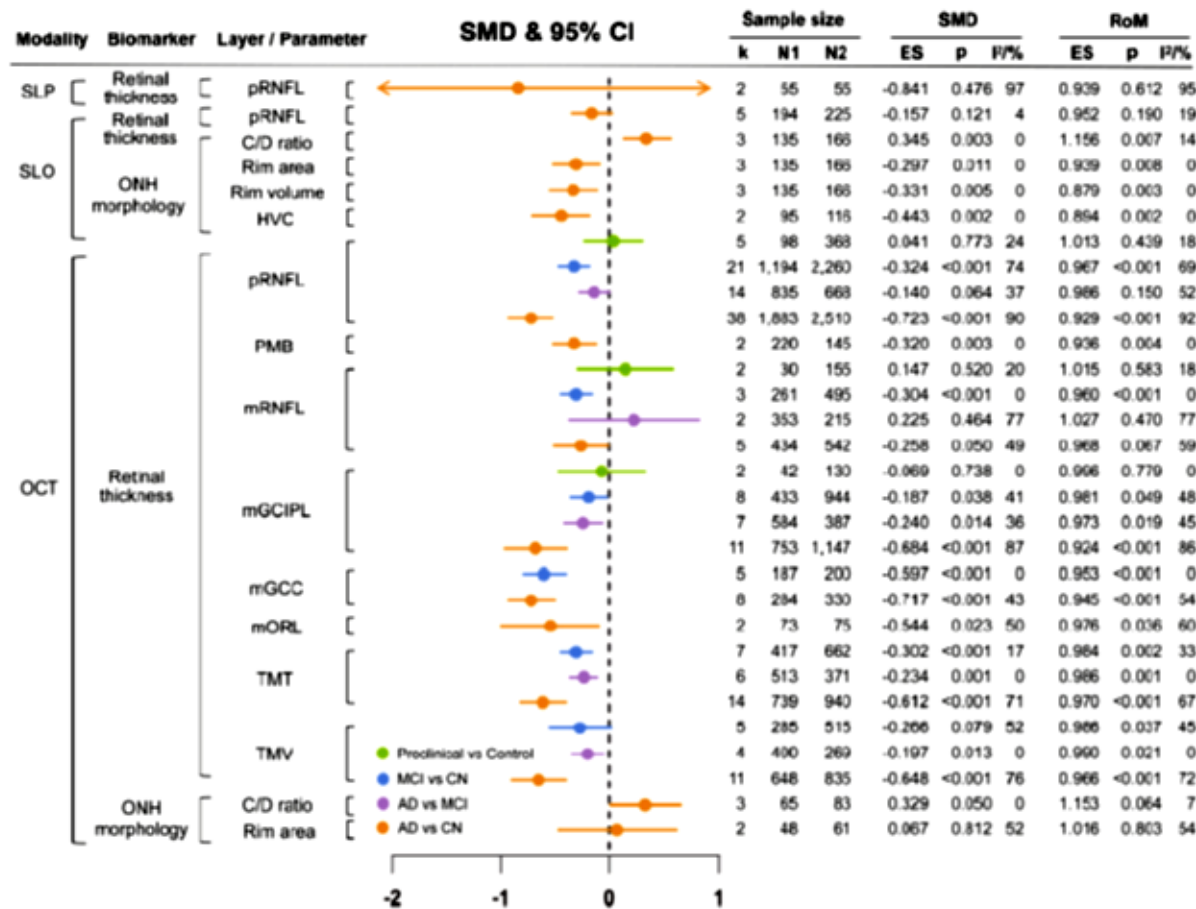
- Retrouve-t-on des atteintes du SNC y compris au niveau rétinien dans la maladie d'Alzheimer?



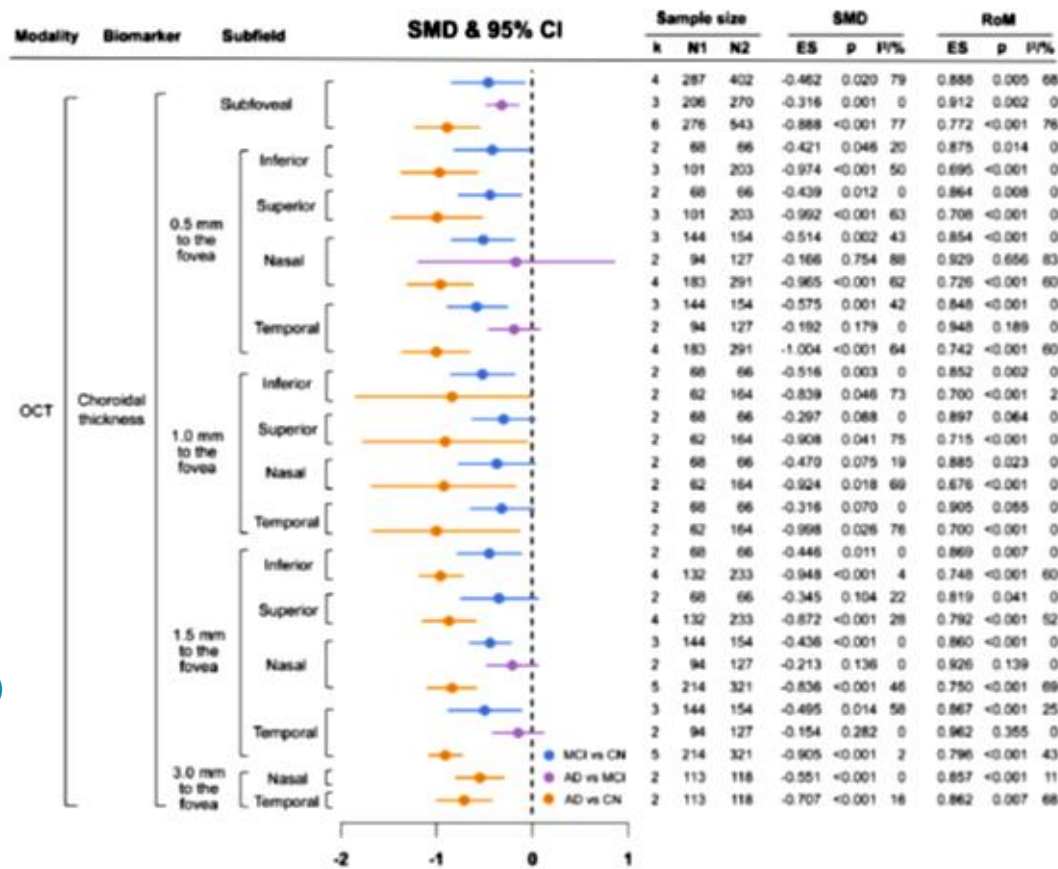
690 results

Page 1 of 69





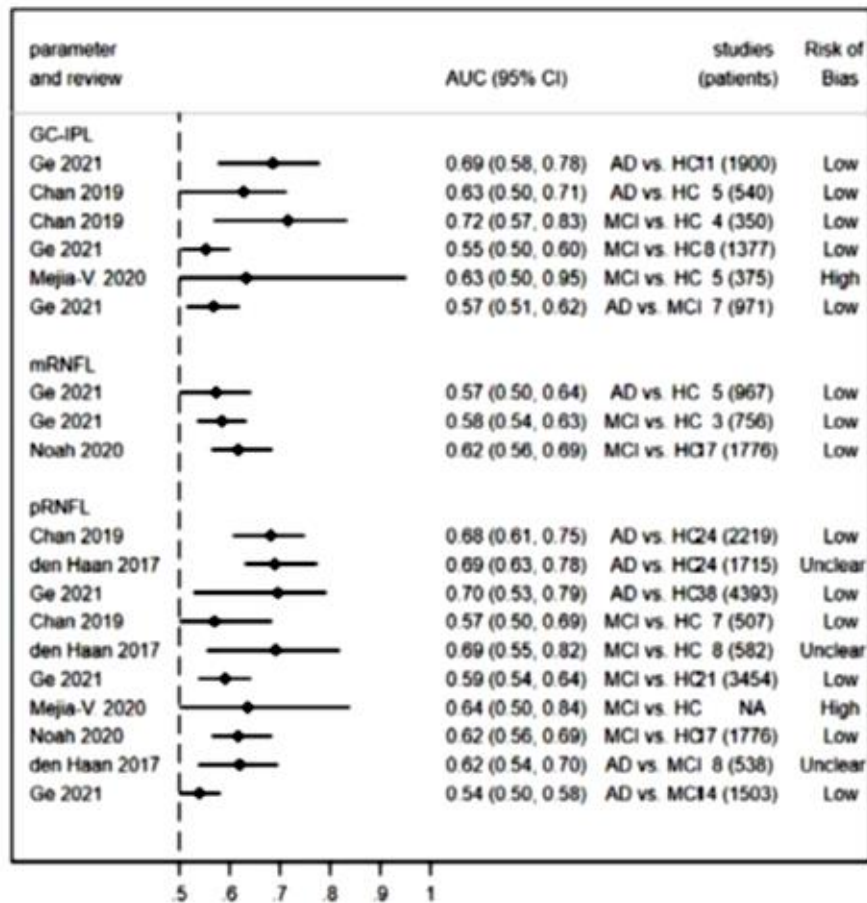
(Ge YJ et coll, Ageing Research Reviews. 2021)

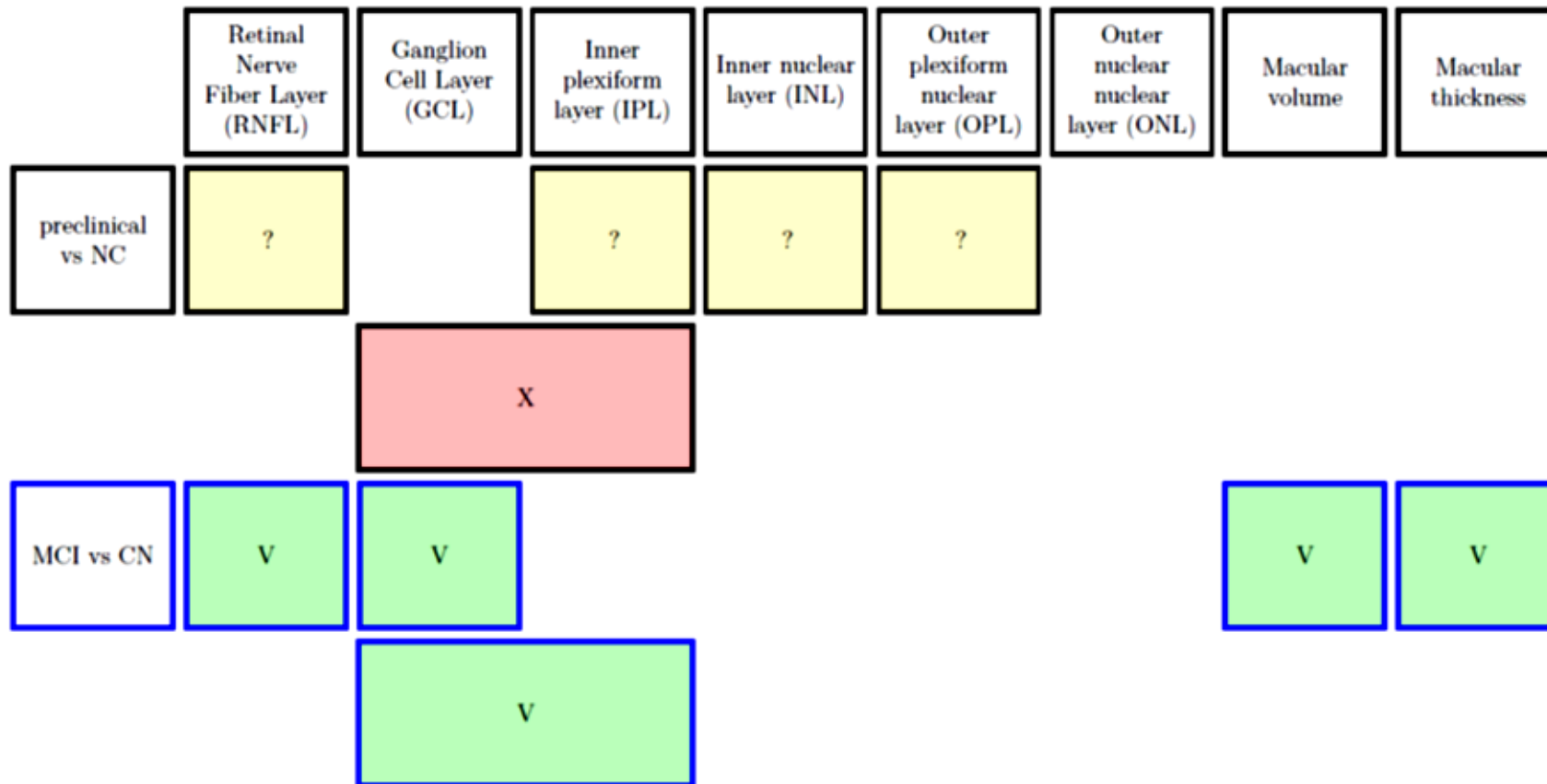


(Ge YJ et coll, Ageing Research Reviews. 2021)



(Costanzo E et coll, JAMA Ophthalmol. 2023)







	Retinal Nerve Fiber Layer (RNFL)	Ganglion Cell Layer (GCL)	Inner plexiform layer (IPL)	Inner nuclear layer (INL)	Outer plexiform nuclear layer (OPL)	Outer nuclear layer (ONL)	Macular volume	Macular thickness
AD vs MCI	?	V					V	V
AD vs CN	V	V				V	V	V
		V						



	Total Thickness	Subfoveal	To the fovea 0.5 mm	To the fovea 1.0 mm	To the fovea 1.5 mm	To the fovea 3.0 mm
MCI vs NC	V	V	V	?	?	
AD vs MCI		V	X		X	
AD vs CN	?	V	V	V	V	V

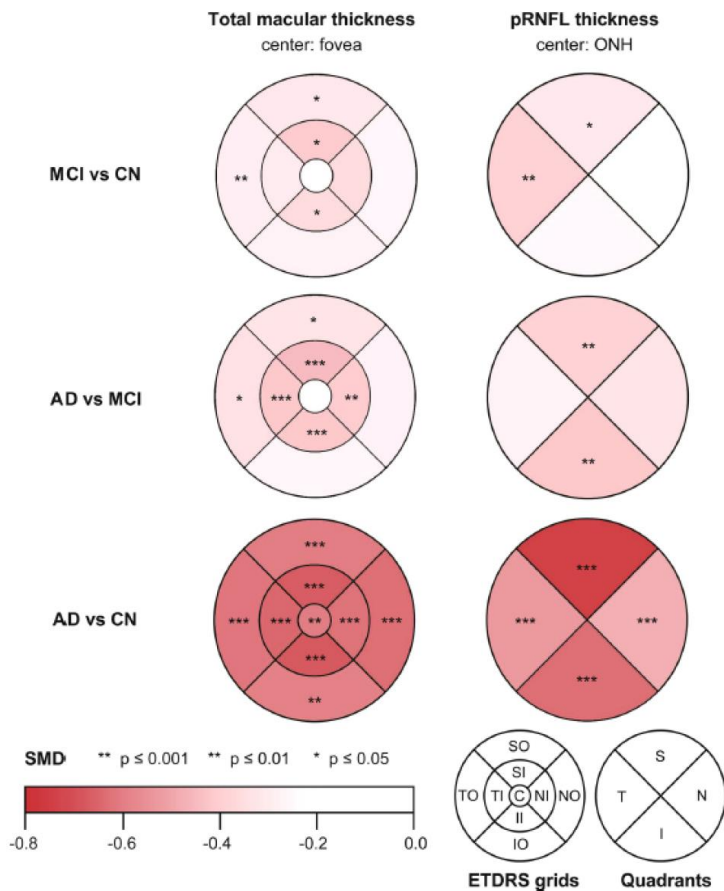


Fig. 3. Sub-regional TMT and pRNFL thickness for the diagnosis of AD and MCI, measured by OCT.

Stars indicate statistical significance of SMD: (***) p -value ≤ 0.001 , (**) $0.001 < p$ -value ≤ 0.01 , and (*) $0.01 < p$ -value ≤ 0.05 . For related detailed data and sectorial data measured by other partition methods, please see Supplementary file 5. Abbreviations: AD, Alzheimer's disease; C, central; CN, cognitively normal; ETDRS, Early Treatment Diabetic Retinopathy Study; I, inferior; II, inferior inner; IO, inferior outer; MCI, mild cognitive impairment; N, nasal; NI, nasal inner; NO, nasal outer; ONH, optic nerve head; p, peripapillary; RNFL, retinal nerve fiber layer; S, superior; SI, superior inner; SMD, standardized mean difference; SO, superior outer; T, temporal; TI, temporal inner; TO, temporal outer.



Tear Fluid

Flow rate and tear function abnormalities
Differential proteomic concentrations
Lysozyme, lipocalin-1, lacritin & dermcidin
Tau & A β altered levels
MicroRNA-200b-5p & eIF4E as biomarkers

Cornea

↓ Corneal nerve fiber density
↓ Branch density
↓ Fiber length

Aqueous Humor

↑ sAPP
↑ A β 40
↑ A β 42

Lens

↑ A β 40
↑ A β 42

Vitreous Humor

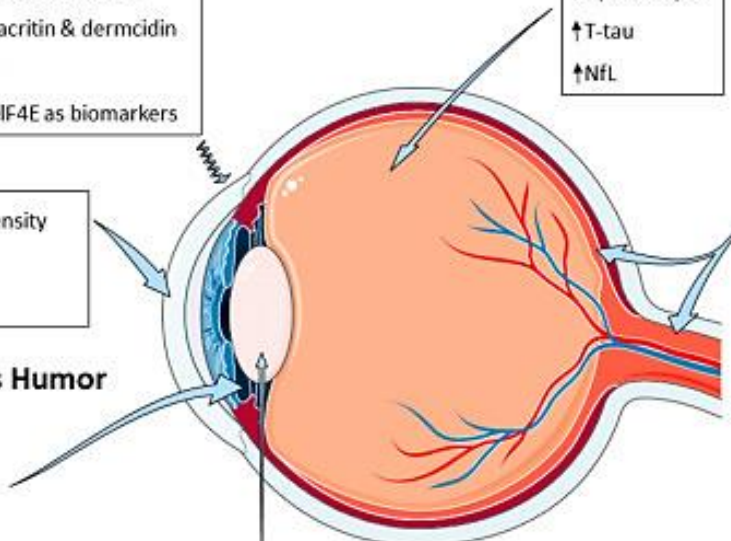
↑ sAPP
↑ A β 40 & A β 42
↑ T-tau
↑ NfL

Retina & Optic Nerve

Histopathological changes
Retinal deposits of A β and tau
Changes in retinal vasculature

Cognitive & Visual Repercussions

Impaired ocular fixation
Difficulty in visual analysis and synthesis
Visual apperceptive agnosia
Difficulty to identify objects
Lack the ability to reconstruct shapes
Prosopagnosia & visual recognition defects
Lack of vision-hand coordination



Daniel Romaus-Sanjurjo

Int. J. Mol. Sci. 2022, 23(5), 2486



Conclusion

- Existence d'une atteinte rétinienne dans maladie d'Alzheimer (également au stade de TNC léger)
- Limites des études: hétérogénéité
- Sujet en expansion (**plus largement le sensoriel**)
- OCT
 - Outil facilement accessible, rapide, faible coût (< 60€)
 - Intéressant en dépistage? Nouveau biomarqueur
 - Utilité de l'IA? (Ganji Z et coll, Photodiagnosis Photodyn Ther. 2025)
- Lésion à corrélérer au profil cognitif+++



En un coup d'œil !

- Ge YJ, Xu W, Ou YN, Qu Y, Ma YH, Huang YY, Shen XN, Chen SD, Tan L, Zhao QH et Yu JT. Retinal biomarkers in Alzheimer's disease and mild cognitive impairment : A systematic review and meta-analysis. *Ageing Research Reviews*. 2021 Aug ; 69:101361. doi :10.1016/j.arr.2021.101361
- Ashraf G, McGuinness M, Khan MA, Obtinalla C, Hadoux X et Wijngaarden P van. Retinal imaging biomarkers of Alzheimer's disease : A systematic review and meta-analysis of studies using brain amyloid beta status for case definition. *Alzheimer's & Dementia (Amsterdam, Netherlands)*. 2023 ; 15:e12421. doi : 10.1002/dad2.12421
- Costanzo E, Lengyel I, Parravano M, Biagini I, Veldsman M, Badhwar A, Betts M, Cherubini A, Llewellyn DJ, Lourida I, MacGillivray T, Rittman T, Tamburin S, Tai XY et Virgili G. Ocular Biomarkers for Alzheimer Disease Dementia : An Umbrella Review of Systematic Reviews and Meta-analyses. *JAMA ophthalmology*. 2023 Jan 1 ; 141:84-91. doi : 10.1001/jamaophthalmol.2022.4845
- Salehi MA, Rezagholi F, Mohammadi S, Zakavi SS, Jahanshahi A, Gouravani M, Yazdanpanah G, Seddon I, Jabbehdari S et Singh RP. Optical coherence tomography angiography measurements in Parkinson's disease : A systematic review and meta-analysis. *Eye (London, England)*. 2023 Oct ; 37:3145-56. doi : 10.1038/s41433-023-02483-2
- López-Cuenca I, Salobar-García E, Elvira-Hurtado L, Fernández-Albarral JA, Sánchez-Puebla L, Salazar JJ, Ramírez JM, Ramírez AI et Hoz R de. The Value of OCT and OCTA as Potential Biomarkers for Preclinical Alzheimer's Disease : A Review Study. *Life (Basel, Switzerland)*. 2021 Jul 19 ; 11:712. doi : 10.3390/life11070712
- Jeevakumar V, Sefton R, Chan J, Gopinath B, Liew G, Shah TM et Siette J. Association between retinal markers and cognition in older adults : a systematic review. *BMJ open*. 2022 Jun 21 ; 12:e054657. doi : 10.1136/bmjopen-2021-054657
- Carazo-Barrios L, Cabrera-Maestre A, Alba-Linero C, Gutiérrez-Bedmar M, Garzón-Maldonado FJ, Serrano V, Cruz- Cosme C de la et García-Casares N. Retinal Neurodegeneration Measured With Optical Coherence Tomography and Neuroimaging in Alzheimer Disease : A Systematic Review. *Journal of Neuro-Ophthalmology : The Official Journal of the North American Neuro- Ophthalmology Society*. 2023 Mar 1 ; 43:116-25. doi : 10.1097/WNO.0000000000001673



Merci de votre attention